

ENDOVASCULAR REPAIR OF THE AORTIC ARCH WITH THE NEXUS STENT GRAFT SYSTEM

ENRIQUE M. SAN NORBERTO*, NOELIA CENIZO, CINTIA M. FLOTA & CARLOS VAQUERO. REC INTERV. CARDIOL. 2020

PATIENT INFORMATION

A 75-year-old male patient underwent emergency surgery for acute type A aortic dissection repair.

REASON TO TREAT

At six months post-op follow up, the distal anastomosis was open and CT angiography revealed the presence of an enlarged aortic arch and descending aorta (from 4.1mm to 5.2mm). Non-eligible for open surgical repair, the cardiac team decided to proceed with endovascular management of the diseased segment of the aorta.

DEBRANCHING

Extra-anatomic reconstruction with right common carotid artery to left subclavian artery bypass (both end-to-side) and proximal ligation with an 8mm ePTFE vascular graft and end-to-side reimplantation of the right common carotid artery on the graft.

NEXUS™ IMPLANTATION

Six weeks later, the endovascular procedure was successfully performed implanting the NEXUS™ Stent Graft System and distally extended with a thoracic stent graft to 3cm above the celiac trunk.

PROCEDURAL OUTCOME

The patient was discharged six days after the endovascular procedure. The three month follow-up CT angiography confirmed the absence of endoleaks and false lumen thrombosis until the end of the implanted stent grafts (figure 2).

COMMENT FROM PUBLICATION*

The NEXUS™ Stent Graft System represents the first branched endo-prosthesis available off-the-shelf in Europe for the endovascular repair of the aortic arch, especially in high-risk patients with complex aortic arch diseases. It is a promising minimally invasive technique. Still, more experience on this regard and a longer follow-up are needed to confirm the promising mid-term results reported.

The practical therapeutic implications include the management of aortic arch diseases like aneurysms and chronic dissections, especially in high-risk surgical patients. This device allows a minimally invasive procedure with no cardiopulmonary bypass, aortic cross-clamping, and circulatory arrest.

Angiology and Vascular Surgery Department

Valladolid University Hospital
Valladolid, Spain



Carlos Vaquero MD, PhD, Prof



Enrique M. San Norberto MD, PhD, MSc

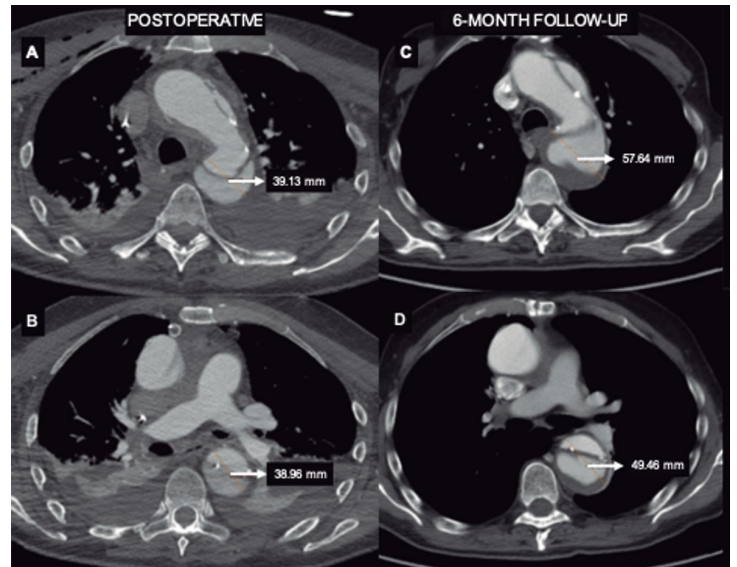


Figure 1.

A, B, C, D: Aortic enlargement after open ascending aorta replacement as seen on the coronary computed tomography angiogram performed at the six month follow-up.

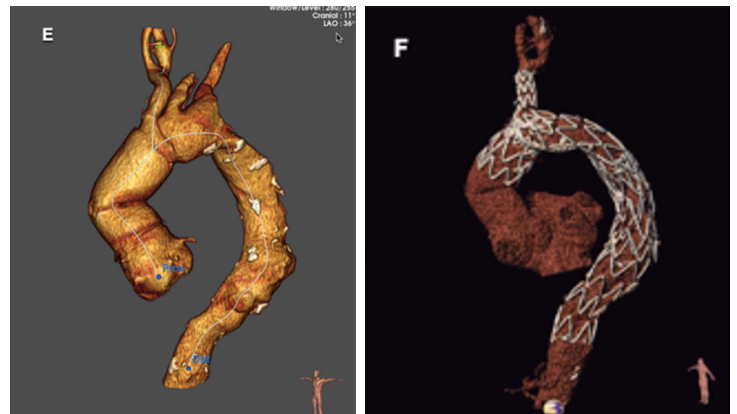


Figure 2.

Three dimensional reconstructions generated from the pre-operative (E) and three month follow up (F) computed tomography angiography.

*San Norberto EM, et al. Endovascular repair of the aortic arch with the NEXUS Stent Graft System. REC Interv. Cardiol. 2020. <https://doi.org/10.24875/RECICE.M20000186>