

DURABILITY OF A CHALLENGING ENDOVASCULAR REPAIR OF THE AORTIC ARCH



PATIENT INFORMATION

A 66-year-old female treated previously with hybrid multibranch thoraco-abdominal aneurysm repair. During follow-up, proximal dedescending degeneration with Type 1A endoleak developed. The aortic arch presented with advanced pathology.



REASON TO TREAT

Due to the already weakened spinal perfusion, the decision was made to perform an endovascular repair versus a frozen elephant trunk hybrid repair as the latter may induce more hemodynamic instability. To get durable seal and fixation, a landing in zone OB was mandatory. The NEXUS™ Aortic Arch Stent Graft System had just achieved CE Mark, so we opted for this approved off-the-shelf, non-compassionate, endovascular solution for this young patient.



CHALLENGES

Gothic, type 3 aortic arch with extreme tortuosity throughout the femoral to aortic valve vasculature (Figure 1).



DEBRANCHING

Debranching was performed 6 weeks prior to the NEXUS™ implantation and was part of a combined transsternal procedure. The latter included 1) off-pump coronary artery bypass surgery, 2) ascending wrap and 3) right common carotid artery to left carotid artery and subclavian artery bypass with reimplantation of left vertebral artery.



NEXUS™ IMPLANTATION

25 March 2019 – Implantation was successful and uneventful.



PROCEDURAL OUTCOME

The patient was discharged and followed up with the aortic centre's standard of care. The 21-month follow-up computed tomography angiography illustrated the integrity and stable position of NEXUS™ as well as complete exclusion of the aneurysm (Figure 2).



PHYSICIANS COMMENT

The NEXUS™ Aortic Arch Stent Graft System maintained hemodynamic stability throughout the procedure with less than 100ml of blood loss. Its design properties of delivery over a through-and-through guidewire, pre-shaped delivery system, and flexible stent graft was revealed to be most helpful to resolve a challenging anatomy with minimal number of endoluminal manipulations. The Dock and Lock® connection between the ascending and arch stent grafts illustrates excellent stability at two-years of follow-up.

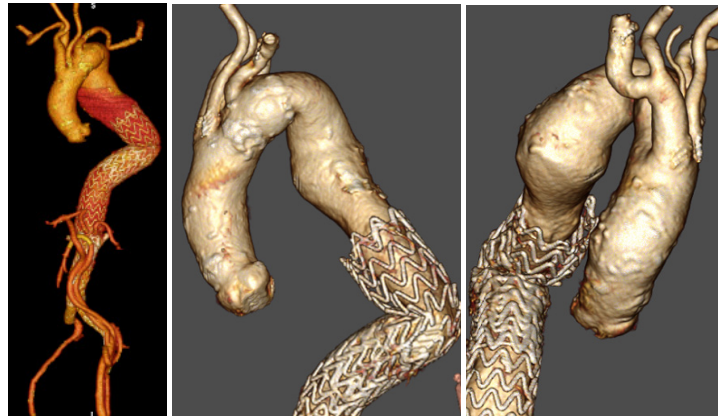
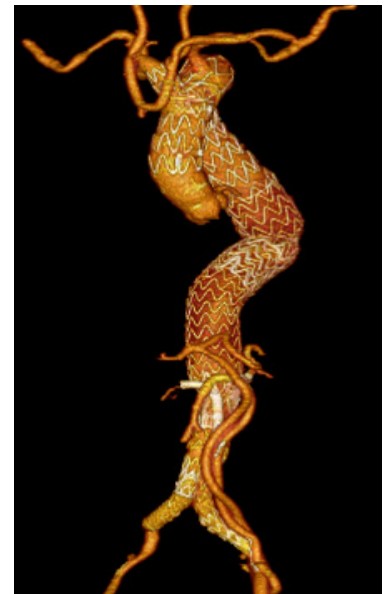


Figure 1.

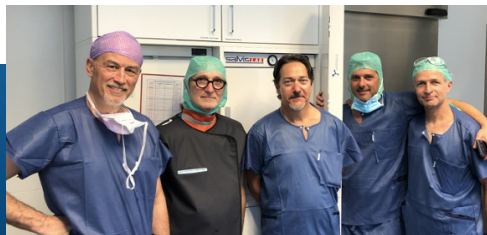Three-dimensional reconstruction of the pre-operative computed tomography angiogram illustrating the lower extremity extra-anatomical bypasses, multibranch thoracoabdominal endovascular repair, and extreme tortuosity of the vasculature.

Figure 2.

Three-dimensional reconstructions generated from the pre-operative CT angiography at 21 months follow-up.



Hirslanden Klinik
Zurich, Switzerland



(L to R) Dr. Michael Szente Varga, Professor Mario L. Lachat (Hirslanden Kilink, Zurich, Switzerland), Dr. Jean Panneton (Sentara Norfolk Hospital, Virginia, USA), Yaniv Marmur, VP of R&D, Endospa Ltd., Herzilya, Israel), Dr. David Planer (Haddasah Medical Centre, Jerusalem, Israel)